

**Ranjeet Deshmukh
Dental College & Research Centre's
Vibrant
Interdepartmental
Scientific
Activity
2022-2023**



VISA





Dr. Vrinda Kolte
Chairperson, VISA Committee



Dr. Himija Karia
Core Committee Member



Dr. Apurva Mohite Khator
Core Committee Member



FOREWORD



Dr. Abhay Kolte, Dean
Professor and Head, Department of Periodontics & Implant Dentistry,
Ranjeet Deshmukh Dental College and Research Centre, Nagpur

“In the longer run and for wide-reaching issues, more creative solutions tend to come from imaginative interdisciplinary collaboration.”

Robert Schiller

It's a matter of great pride and satisfaction to see the sapling of VISA Activity growing over the years and establishing itself into one of the major interdepartmental scientific activities conducted by the institute. The primary objective with which the activity was started was to showcase the quality of work performed by every department/specialty amongst the colleagues and to have better interdepartmental cooperation. It also enables others to get motivated in trying innovative treatment modalities for better patient care.

On several occasions the dental anomaly or condition would require an interdisciplinary approach integrating the knowledge, skills and experience of all the disciplines of dentistry, medicine and its associated fields into comprehensive treatment to maximize results. Rapid and comprehensive scientific and technological advances have made it difficult for any single clinician or specialists to keep abreast of recent understandings and knowledge in their fields. Thus, to decrease chances of any compromise in the treatment and increase patient benefits, an interdisciplinary approach has become essential. Though there can be initial reluctance from many clinicians but overall, a combined multidisciplinary approach is beneficial for the patient and the clinicians alike.

This edition has published interesting cases treated in the respective Departments in the past one year. It is heartening to see the quality of work done in all the departments which really speaks volumes about the overall dental health care we all render to our patients. The commitment of the staff and students involved in the patient care is worth appreciating and reflects upon our own selves in terms of clinical skills and knowledge. Any institution is known by the people working within where some are inclined towards clinical activities and the others in teaching endeavors.

I take this opportunity to congratulate the members of the VISA activity who have put in a lot of efforts to bring this publication well in time for all of us. Such initiatives ensure that we all progress together in the profession.

Dr. Abhay Kolte
Dean
Ranjeet Deshmukh Dental College and Research Centre



FROM THE DESK OF VICE DEAN (Administrative)



Dr. Ramkrishna Sheno, Vice Dean (Administrative),
Professor and Head, Department of Oral Surgery, PG Director,
Ranjeet Deshmukh Dental College and Research Centre, Nagpur

I congratulate team VISA for taking out the sixth edition of VISA magazine which was started in 2016. This indeed is the materialization of all the efforts put in by the team and the post graduate students in presenting the best of cases during this year and fostering better coordination between all the departments.


The brain storming sessions are always healthy and they aid the clinicians in making better diagnosis and treatment plan and the end beneficiaries are the patients.

Wishing the team VISA a very successful new year.

Dr. Ramakrishna Sheno
Vice Dean (Administrative)
Ranjeet Deshmukh Dental College and Research Centre



FROM THE DESK OF VICE DEAN (Clinical)



Dr. Mukta Motwani, Vice Dean (Clinical),
Professor and Head, Department of Oral Medicine and Radiology
Ranjeet Deshmukh Dental College and Research Centre, Nagpur

The VISA team has successfully published six issues of this magazine and hopefully this venture continues in the future as well. Even during COVID times, the VISA presentations were conducted on an online platform which is a great effort put in by the VISA team.

I appreciate team VISA and all the Post Graduate students for presenting such interesting cases and making this activity worthwhile.

Regards

Dr. Mukta Motwani

Vice Dean (Clinical)

Ranjeet Deshmukh Dental College and Research Centre



FROM THE CONVENOR'S DESK



Dr. Vrinda Kolte,
Professor, Department of Oral & Maxillofacial Surgery
Ranjeet Deshmukh Dental College and Research Centre, Nagpur

It gives me immense pleasure to present sixth issue of Ranjeet Deshmukh Dental College and Research Centre's VIBRANT INTERDEPARTMENTAL SCIENTIFIC ACTIVITY - VISA. VISA activity started in 2016 to inculcate interdepartmental knowledge exchange among all. All departments present their clinical cases which need interdisciplinary approach in their management.

On behalf of my VISA team, I extend my heartfelt thanks to our management and Dean for shouldering the responsibility on us and support for the smooth conduction of activity throughout the year.

I congratulate all departmental staff and postgraduate trainees for their wonderful scientific contribution to make this activity successful!

Regards,

Dr. Vrinda Sunil Kolte

Convenor, VISA Committee

Ranjeet Deshmukh Dental College and Research Centre



Contents		
Sr. No.	Title	Page No.
1	Prosthetic Rehabilitation of Patient with Anotia	1
2	Conservative Management Of Mutilated Maxillary Central Incisor – An Endodontic Periodontics Interdisciplinary Approach	4
3	A Novel Approach in Periodontally Accelerated Osteogenic Orthodontics (PAOO)	10
4	Ameloblastoma with Dentigerous cyst	14
5	Rehabilitation of Patient with Congenital Asymmetry	19
6	Central Giant cell Granuloma	25
7	Conservative Surgical Management of Odontoma in 11 year old Child	28



Prosthetic Rehabilitation of Patient with Anotia



Presented by:

Dr. Rohit Patil, Dept. of Prosthodontics and Implantology

Dr . Simran Sangani, Dept. of Oral and Maxillofacial surgery

Introduction: Maxillofacial defects may cause severe emotional trauma concerning facial esthetics and social acceptance of the patient. By rehabilitating such defects, we not only restore the normalcy on the patient’s face but also give him the confidence to interact with society and live in a social environment.

The utilization of extraoral implants in maxillofacial rehabilitation provides patients with better esthetics, retention, and stability than other retention methods.

Traditional methods include the use of tissue undercuts, spectacles and adhesives. These methods are often related to problems with retention, stability, discomfort, adverse tissue reactions, accelerated discoloration, and deterioration of prosthesis.

Compare to surgical reconstruction which may have uncertain results, Implant retained auricular prosthesis provide several advantages like convenience, consistent retention and positioning, marginal integrity, longevity, and elimination of the need for adhesives. The overall survival rate of mastoid implant is 95.7%.

Several attachments are available for the retention of the implant-retained prosthesis. The implant retained auricular prosthesis usually requires a bar with clips or retentive elements along with the prosthetic ear.

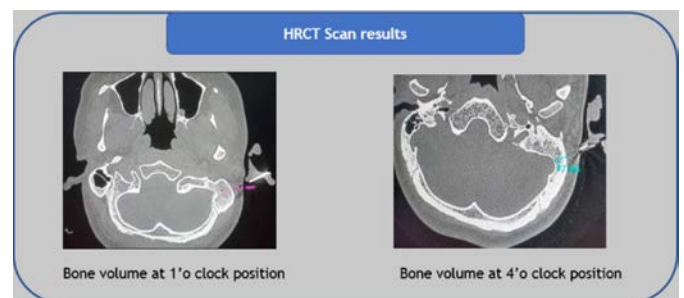
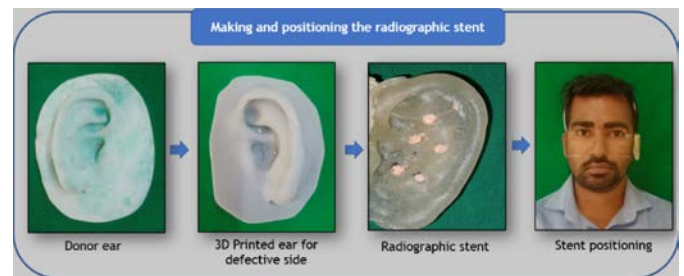
Sculpting an ear prosthesis is quite difficult and time consuming. Three-dimensional (3D) imaging technologies allow us to produce

accurate dimensions of a patient’s healthy and defective side.

This case study illustrates the rehabilitation of a patient missing his left ear by birth with prosthetically driven implant placement and fabrication of the implant retained auricular prosthesis.

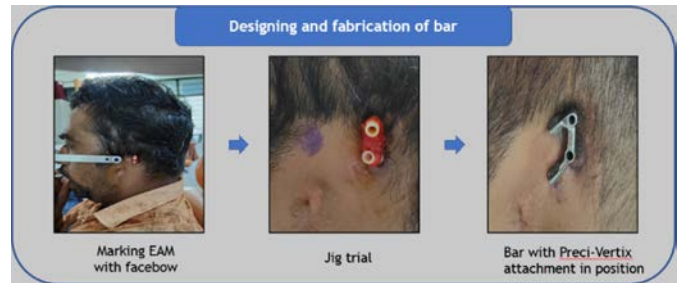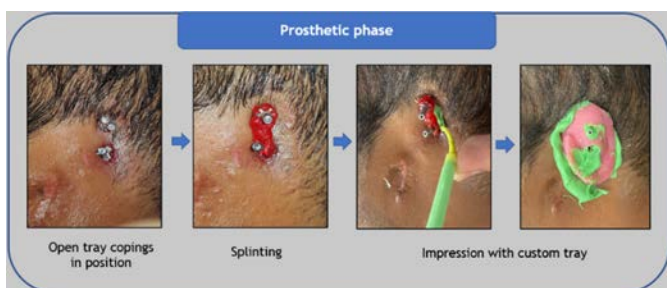
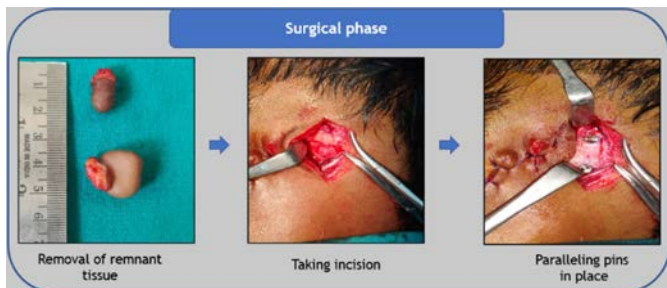
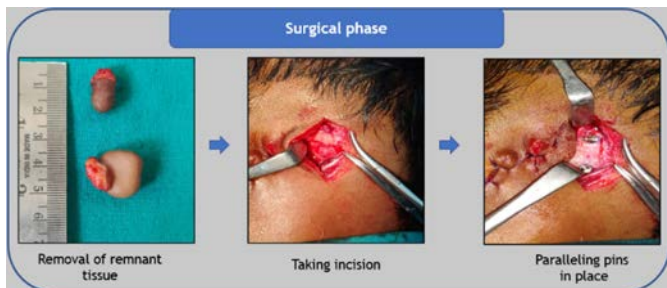
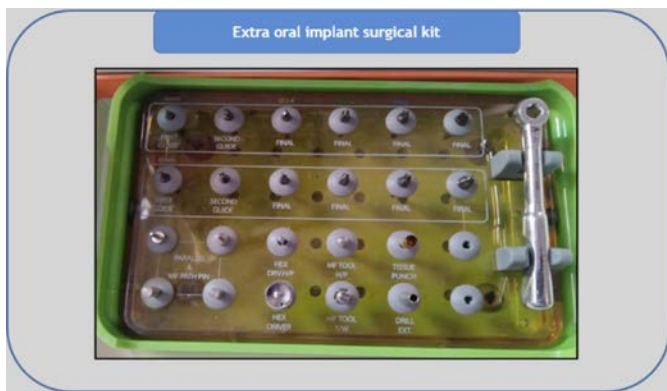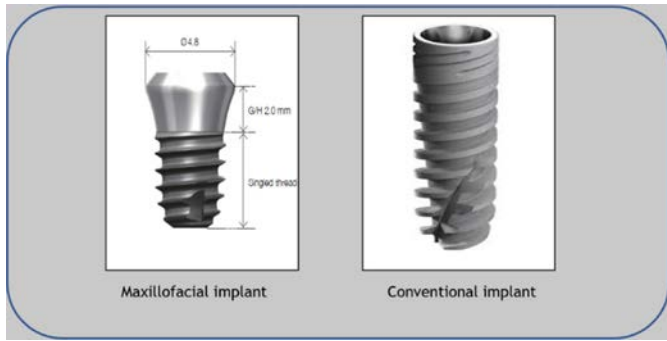
Case report: A 27 year old male patient was referred to the department of Prosthetic dentistry with the chief complaint of facial disfigurement due to his missing left ear.

The defect was congenital and there is no presence of external acoustic meatus. The patient was extremely concerned about his facial disfigurement and wants a prosthesis for his missing ear to regain some normalcy of appearance.





VIBRANT INTERDEPARTMENTAL SCIENTIFIC ACTIVITY - VISA



Discussion: Patients with auricular deformity or absence of auricle endures psychological affliction.

The aim of maxillofacial rehabilitation is to provide a suitable prosthesis for patients with facial defects so that they can be confident enough to face society and accept the challenges of life.

Compare to surgical reconstruction which may have uncertain results a good alternative is to develop an auricular prosthesis with a suitable material. Magnet and bar-clip retention are the two primary forms of retention used in the auricular region. The bar-clip system provides good retention for the prostheses. Fabricating a unilateral prosthesis remains a more challenging task as compared to a bilateral auricular prosthesis as this presents a constant comparison with a natural counterpart.

Three-dimensional systems facilitate the production of a mirror image of the auricular prosthesis with a high level of accuracy, alleviating most of the limitations of the conventional prosthesis. Silicone is the material of choice for facial prostheses because of its flexibility and life-like appearance.

In this case, RTV silicone was used. Intrinsic stains were used for the prosthesis coloration as these are more color stable and provided better esthetic results.

Conclusion: Although challenging, maxillofacial prosthesis can be an excellent mode of rehabilitation of patients if successful. The use of three-dimensional (3D) printing



technology for the placement of implants and fabrication of prosthesis is helpful. This method eliminated the conventional

laboratory steps and exactly duplicate the ear on the opposite side for fabrication of the prosthesis.



Conservative Management of a Mutilated Maxillary Central Incisor- An Endodontic-Periodontic Interdisciplinary Approach.



Presented by:

Dr. Anushree Talnikar, Dept. of Conservative dentistry and Endodontics

Dr. Divya Trivedi, Dept. of Periodontics

Introduction: An attempt to save a tooth never goes in vain when its root is strong. A tooth may require extra reinforcement for better long-term outcomes. Successful restoration of a root-filled teeth requires an effective coronal seal, protection of the remaining tooth, restored function and acceptable aesthetics.⁽¹⁾

Post and cores are one of the treatment modalities which are indicated in cases with compromised crown structure. However, root fractures are one mode of failure for post restored teeth. Therefore, the crown and post preparation design features should be such that they reduce the chances of root fracture. A ferrule is a metal ring or cap intended for strengthening.⁽²⁾

A dental ferrule is an encircling band of cast metal around the coronal surface of the tooth. It has been proposed that, the use of a ferrule as part of the core or artificial crown may be of benefit in reinforcing root-filled teeth. A protective or 'ferrule effect' could occur owing to the ferrule resisting stresses such as functional lever forces, the wedging effect of tapered posts and the lateral forces exerted during the post insertion. Gingival management and crown lengthening procedures may be imperative in some cases when the clinical crown length is insufficient for an adequate ferrule effect.^(3,4)

To maintain the relationship of tissue and epithelial attachments around the teeth, specifically the supracrestal connective tissues (formerly known as the biologic

width); the connection between the hard and soft tissues must be in harmony. Crown lengthening procedures are beneficial for both natural and restored teeth in functional and aesthetic ways, it also contributes to the harmony of the face. The correct diagnosis and restorative plan play a major role in the surgical workflow. When there is supracrestal connected tissue impingement, the original gingival apparatus either re-establishes itself or, worse, disintegrates.⁽⁵⁾

After adequate amount of ferrule is obtained, the endodontic procedures are performed to eliminate any kind of periapical pathology; clean and shape the root canals; and fill the root canal space to avoid further re-infections. In cases with wide apices due to long term periapical infections, closure of the apex with MTA is required for correction, followed by the placement of a custom-made cast post and core. To restore the functions and aesthetics a full coverage porcelain fused metal prosthesis is given.

Case Report: A 33-year-old male patient had reported to the Department of Conservative Dentistry and Endodontics VSPM's Dental College and Research Centre, Nagpur with a chief complaint of poor aesthetics due to fractured prosthesis in the upper front region of the jaw and had a desire to get it restored. Clinical examination revealed fractured prosthesis along with the tooth 21 which led to destruction of the tooth up to the cervical level as shown in figure 1. There was no tenderness on vertical percussion and no



mobility associated with the tooth 21.

On radiographic examination, 21 was endodontically treated with improper obturation, but there were no signs of periapical infection and periodontal ligament widening. Radiographically only 2mm of crown was visible (Figure 2). Hence our goal was to restore the form and function of the lost tooth structure. The treatment plan with the involved tooth included crown lengthening procedure, revision of the previous endodontic treatment, custom made cast post and core followed by a porcelain fused metal prosthesis.

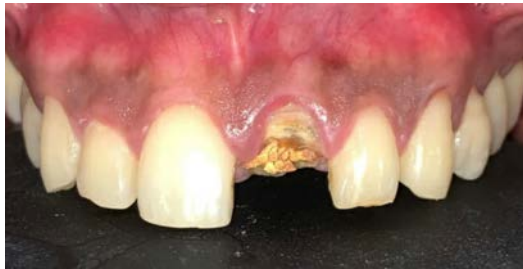

Figure 1- Pre operative clinical picture with the tooth 21

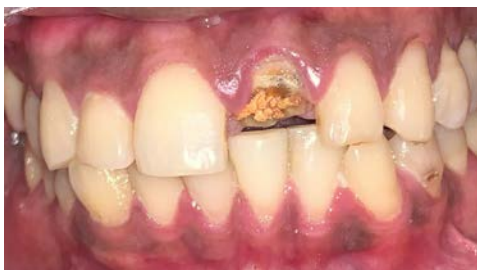

Figure 1- Pre operative clinical picture with the tooth 21

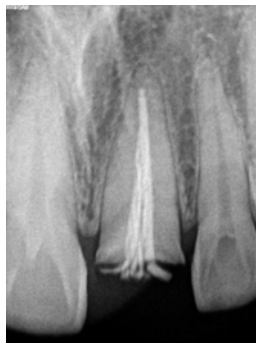

Figure 2- Pre-Operative Radiograph with the tooth 21

Examination: The patient's chief complaint was taken on the initial appointment, and it emphasized on his aesthetic problems. The medical history did not reveal any general health conditions. The dental history addressed, including his oral hygiene habits, other practices, and any previous dental treatment other than Orthodontic work. Clinically, only 1mm of irregular tooth was visible, gutta percha of previous root canal treatment was exposed. Gingival overgrowth could be seen on the mesial and distal aspect of the tooth.

Preliminary phase: Complete oral prophylaxis was done prior to all endodontic and surgical procedures.

Restorative phase: No restorations were required at the current situation, but removal of previous root canal filling, all carious and friable tooth structures were removed.

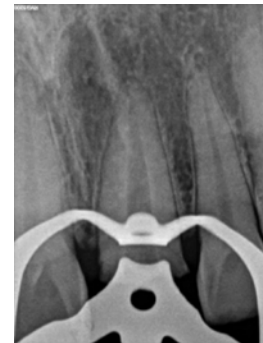

Figure 3- radiograph of the tooth 21 after removal of previous root canal filling.

Surgical phase: The magnitude of the biological width was added to the amount of supra-crestal tooth structure needed for placement of the prosthetic margin. The level of the osseous crest was lowered based on this amount using a combination of rotary and hand instruments. The original bone width was maintained at all sites after ostectomy. For adjacent teeth, osseous resection was in keeping with positive architecture. Osseous resection was performed by one examiner.



An inverse bevelled incision and full-thickness mucogingival flap reflection was performed. Osseous resection was performed as described above. The soft tissue flaps were positioned at the bony crest and sutured. Patients were prescribed a non-steroidal anti-inflammatory analgesic and instructed to rinse with 0.12% chlorhexidine gluconate twice daily for 2 weeks. Sutures were removed 14 days after the surgery.

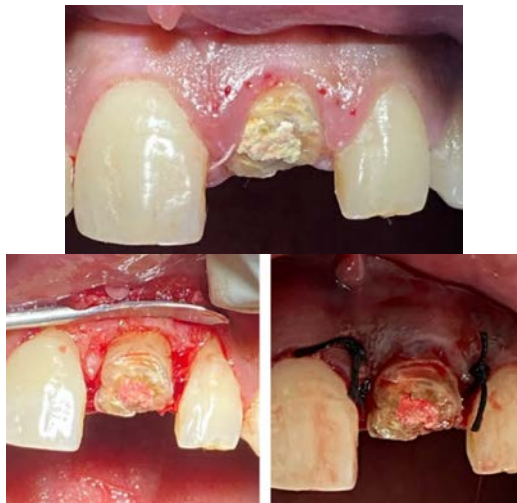


Figure 4- Periodontal surgery-maintaining the gingival zenith, osseus resection and suturing.

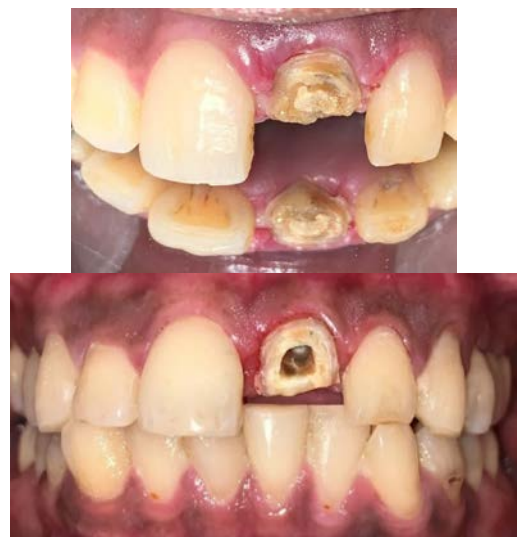

Figure 5- clinical picture after complete removal of old root canal filling and crown lengthening procedure.

Endodontic phase: Endodontic revision was done. Endostar RE re endo rotary file system was used in the sequence of Nr1(12/30), Nr2 (08/30), Nr3 (06/30), Nr4 (04/30) which is designed in a crown down technique. Working length was determined using a 15k handfile (Mani). Endostar E3 Azure 4% 40 rotary file along with irrigation with sodium hypochlorite followed by normal saline and 2% chlorhexidine was used for the biomechanical preparation. The tooth had a wide apex which was corrected with MTA (Cerkamed White MTA).

Thermoplasticized gutta percha was used for obturation using bulk fill technique at the level seen in figure 6, which was as per the requirement of Post length (Calamus Dual System, Dentsply Sirona); according to the conservationist's philosophy.

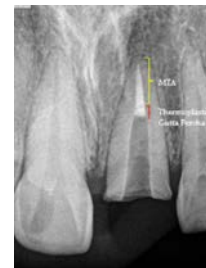


Figure 6- radiograph of post space with apical one third filled with MTA and gutta percha

After the post space was cleaned and lubricated with mineral oil, direct wax pattern of the canal was taken carefully on a plastic pinchet with medium fusing type II inlay wax.

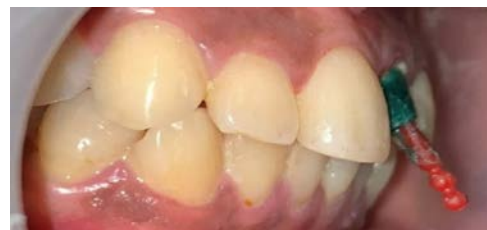

Figure 7- Wax pattern for fabrication of the custom cast post.



The wax pattern was invested and a cast metal post and core was obtained.

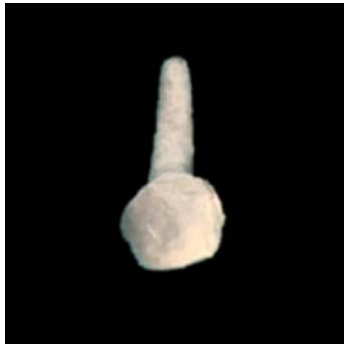

Figure 8- Cast post and core

The Post was tried to check the fit and then cemented with zinc phosphate cement (Harvard cement).

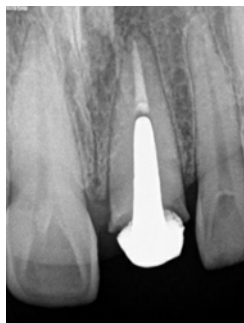
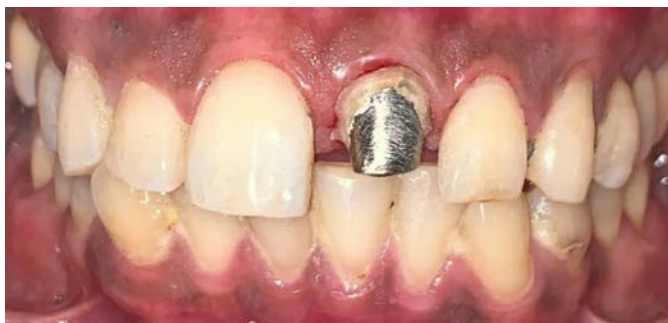

Figure 9- cementation of the cast post and core.

Shade matching was done using a VITA shade guide. Impression was taken with a rubberbased impression material (Zhermack putty) and a porcelain fused metal prosthesis was fabricated for the tooth 21.

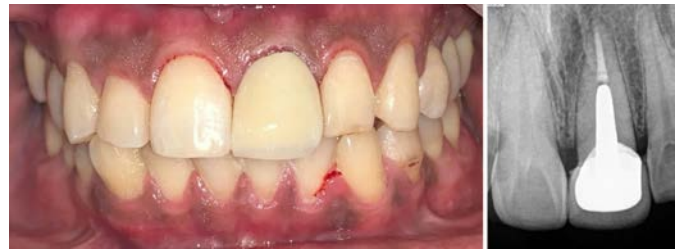

Figure 10- Immediate Post prosthesis cementation with 21

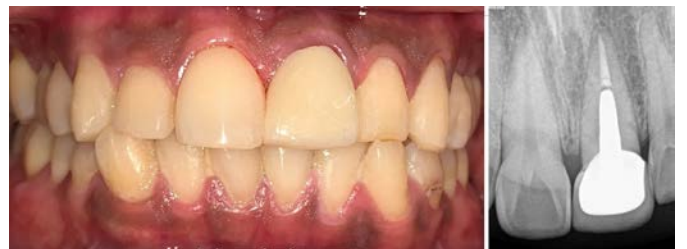

Figure 11- 6 months follow-up clinical picture with 21



Figure 12- 6 months follow-up

Discussion: *“Every tooth in man’s head is more valuable than a diamond”* – Miguel de Cervantes.

Rehabilitation of a mutilated endodontically treated teeth is often a challenge. Modern endodontics offers advancements in technologies, procedures and materials which gives many treatment options to save one’s natural tooth. Saving a natural tooth is important as no denture, bridge or implant will look, feel, and function like a natural tooth.⁽⁶⁾

For rehabilitation of traumatised anterior teeth, both aesthetic and mechanical aspects



should be considered. Post and core is considered as the foundation restoration for such endodontically treated anterior fractured teeth followed by placement of a full coverage crown.⁽⁷⁾

A minimum of 2 mm ferrule is needed for a good post and core with predictable results in terms of retentive and prosthetic concerns. Crown lengthening involves the surgical removal of hard and soft periodontal tissues to gain supracrestal tooth length, allowing for longer clinical crown and reestablishment of the biological width.⁽⁸⁾

A pre-endodontic surgical phase was carried out because there was no visibility due to the gingival overgrowth and no accessibility for the rubber dam isolation. In the following case, the patient had a root filled tooth, with a prosthesis which fractured along with the tooth and only 1mm of irregular clinical crown was available. Revision of the previous endodontic treatment was done as the gutta percha was exposed and there were possible chances of coronal leakage. MTA barrier had to be placed at the apex to correct the wide apex.

Custom built cast post and core restoration offers an advantage in the form of perfect fit with minimal luting cement interface and inherent antirotation mechanism in teeth with uneven, ovoid, elliptical or conical root canal, as in the present case. According to a study done by Gegauff AG, a 2 mm ferrule obtained by crown lengthening resulted in a reduction of static load fracture. The advantage of using custom-made cast post and cores during root canal and crown preparation is their increased

strength and minimal loss of tooth structure. The retention of tooth structure is crucial for a successful post and core restoration since the strength of the tooth strongly correlates with the amount of remaining sound tooth structure. The prefabricated posts, such as those made of stainless steel, titanium, fibre posts (carbon, glass), and ceramic posts (Zirconia), have round crosssections, and they may have different surface qualities (serrated, smooth, threaded, and roughened), as well as shapes like parallel and tapered, and they come with corresponding drills for creating post spaces.⁽⁹⁾

Therefore, more tooth structure must be removed in order to get a precise fit with these prefabricated posts than with a custom cast post and core. Along with approximation and adaptation to the morphology of the constructed canal, an anti-rotation feature must also be given.⁽¹⁰⁾

A tooth with a cast post and core requires a porcelain fused metal prosthesis, as there is limited bonding of all ceramic crown with cast metal.⁽¹¹⁾

In several retrospective studies it is concluded that the mean survival rate of teeth restored with custom post and core with a PFM prosthesis is 12.5 years and maximum up to 5 years.^(9,10,12)

Conclusion: The results of this study indicated that the combination of simulated surgical crown lengthening and cast post prosthesis was effective in restoring the maxillary central incisor. The biologic width re-established at 6 months follow up.

References:

1. Stankiewicz NR, Wilson PR. The ferrule effect: a literature review. *Int Endod J* [Internet]. 2002 Jul 1 [cited 2023 Mar 3];35(7):575–81. Available from: <https://onlinelibrary.wiley.com/doi/full/10.1046/j.1365-2591.2002.00557.x>
2. Kutesa-Mutebi A, Osman YI. Effect of the ferrule on fracture resistance of teeth restored with prefabricated posts and composite cores. *Afr Health Sci*. 2004;4(2):131–5.



3. Crown Lengthening Procedures-A Review Article. [cited 2023 Mar 3]; Available from: www.iosrjournals.org
4. MamounDr. JS. On the ferrule effect and the biomechanical stability of teeth restored with cores, posts, and crowns. *Eur J Dent* [Internet]. 2014 [cited 2023 Mar 3];8(2):281. Available from: [/pmc/articles/PMC4054064/](http://pmc/articles/PMC4054064/)
5. Gegauff AG. Effect of crown lengthening and ferrule placement on static load failure of cemented cast post-cores and crowns. *J Prosthet Dent* [Internet]. 2000 Aug;84(2):169–79. Available from: <https://linkinghub.elsevier.com/retrieve/pii/S0022391300601403>
6. Saving Your Natural Tooth - American Association of Endodontists [Internet]. [cited 2023 Mar 4]. Available from: <https://www.aae.org/patients/root-canal-treatment/saving-natural-tooth/>
7. Faria ACL, Rodrigues RCS, de Almeida Antunes RP, de Mattos M da GC, Ribeiro RF. Endodontically treated teeth: Characteristics and considerations to restore them. *J Prosthodont Res*. 2011;55(2):69–74.
8. Lanning SK, Waldrop TC, Gunsolley JC, Maynard JG. Surgical Crown Lengthening: Evaluation of the Biological Width. Vol. 74, *J Periodontol*. 2003.
9. Gegauff AG. Effect of crown lengthening and ferrule placement on static load failure of cemented cast post-cores and crowns. *Journal of Prosthetic Dentistry* [Internet]. 2000 Aug 1 [cited 2023 Mar 4];84(2):169–79. Available from: <http://www.thejpd.org/article/S0022391300601403/fulltext>
10. Zhou L, Wang Q. Comparison of fracture resistance between cast posts and fiber posts: a meta-analysis of literature. *J Endod* [Internet]. 2013 Jan [cited 2023 Mar 4];39(1):11–5. Available from: <https://pubmed.ncbi.nlm.nih.gov/23228250/>
11. Alshouibi E, Alaqil F. Masking a Metal Cast Post and Core Using High Opacity e.max Ceramic Coping: A Case Report. *J Int Soc Prev Community Dent* [Internet]. 2019 [cited 2023 Mar 6];9(6):646. Available from: [/pmc/articles/PMC6905318/](http://pmc/articles/PMC6905318/)
12. Martino N, Truong C, Clark AE, O'Neill E, Hsu SM, Neal D, et al. Retrospective analysis of survival rates of post-and-cores in a dental school setting. *J Prosthet Dent* [Internet]. 2020 Mar 1 [cited 2023 Mar 4];123(3):434. Available from: [/pmc/articles/PMC6982572/](http://pmc/articles/PMC6982572/)



A Novel Approach in Periodontally Accelerated Osteogenic Orthodontics (PAOO) : A case Report



Presented by:

Dr . Prabhnoor Tuli, Dept. of Periodontics

Introduction: Orthodontic tooth movement is considered a 'periodontal phenomenon', as conventional orthodontic movements lead to periodontal ligament compression, thereby activating the dynamics of crestal bone resorption and apposition.

Many patients with malocclusions are reluctant for orthodontic treatment because of its drawn out treatment time.

In order to meet the constant demand of short treatment time while preserving the integrity of periodontal structures, an alternate treatment approach has been popularized known as corticotomy facilitated orthodontics

History: Corticotomy-facilitated tooth movement was first described by L.C. Bryan in 1893.

However it was first introduced by Kole in 1959 (Bone-block movement).

Harold Frost in 1983 identified it as Rapid acceleratory Phenomenon (RAP).

A more recent surgical orthodontic therapy was introduced by Wilcko et al. which included the innovative strategy of combining corticotomy surgery with alveolar grafting in a technique referred to as Accelerated Osteogenic Orthodontics (AOO) and more recently to as PAOO.

Biology underlying PAOO: PAOO is a clinical procedure that combines selective alveolar corticotomy, particulate bone grafting, and the application of orthodontic forces.

Recent evidence suggests a localized osteoporosis state, as a part of a healing event

called regional acceleratory phenomenon (RAP), may be responsible for the rapid tooth movement after PAOO.

The two main features of RAP in bone healing include decreased regional bone density and accelerated bone turnover, which are believed to facilitate orthodontic tooth movement.

The RAP begins within a few days of injury, typically peaks at 1–2 months, usually lasts 4 months in bone and may take 6 to more than 24 months to subside.

Case selection for PAOO:

1. Class I with moderate to severe crowding.
2. Class II with extraction (To accelerate Canine retraction after premolar extraction or Enmass retraction of anterior teeth) or expansion.
3. Mild class III cases.
4. To facilitate eruption of Impacted teeth.
5. Molar intrusion and Openbite correction.
6. Molar Uprighting.
7. Molar Distalisation.
8. Arch expansion

Contra-indications:

1. Severe Class III cases.
2. Active periodontal disease or gingival recession.
3. It should not be considered as an alternative for surgically assisted palatal expansion in the treatment of severe posterior cross-bite.
4. It should not be used in cases where Bimaxillary protrusion is accompanied with a gummy smile.

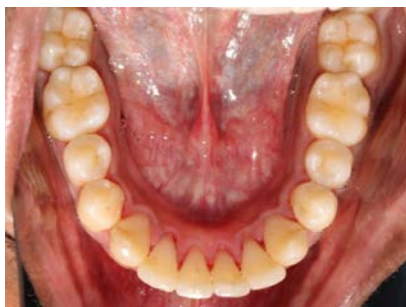
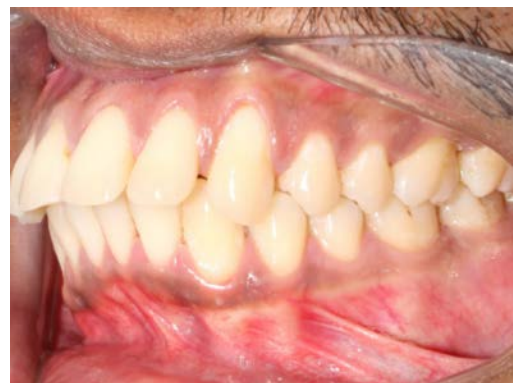
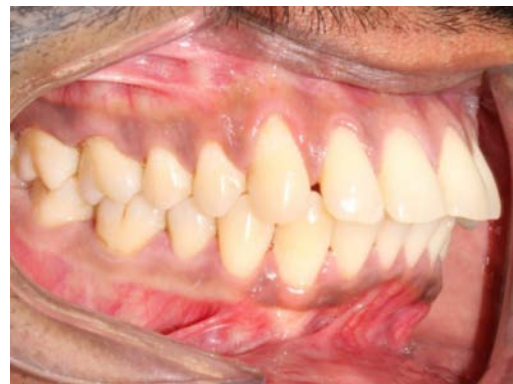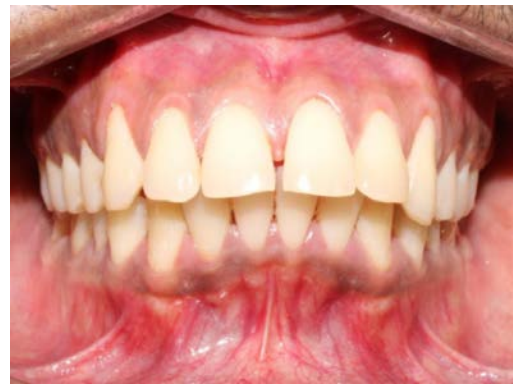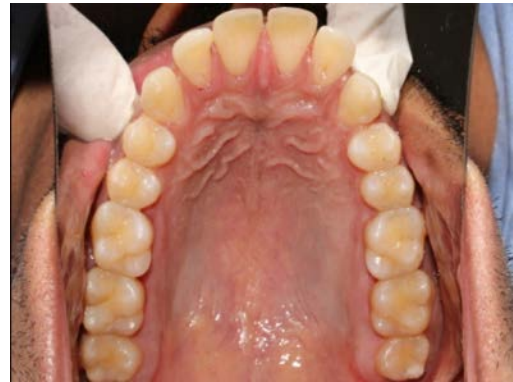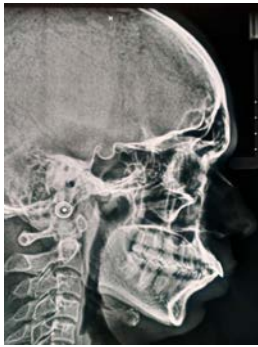5. Patients with uncontrolled diabetes mellitus, compromised immune system and patient in compliance.
6. Uncontrolled Osteoporosis or other bone diseases.

Advantages:

1. Reduced treatment time: this technique will reduce treatment time to 1/3rd to 1/4th time of conventional orthodontics.
2. Less root resorption due to decreased resistance of cortical bone.
3. More bone support due to the addition of bone graft.
4. Improved periodontal support, both gum and bone support for the teeth.
5. History of relapse reported to be very low.
6. It can be used to expedite the rate of movement of Individual teeth or Dental segments, i.e. canine and incisor retraction.
7. Alveolar grafting also benefits the patient by repairing bony dehiscences and fenestrations.

Case report: Patient's name: Mr. Shailendra Bijewar, Age: 29 Years, Sex: Male, Chief Complaint: Unesthetic appearance due to malaligned teeth and wants to get them corrected.





LATERAL CEPHALOGRAM

- Dentition – permanent
- Molar relation - class I molar relation on both side
- Canine relation – class I canine relation on both side
- Overjet = 3 mm
- Overbite= 2 mm
- After recruitment, patient was throughly examined.
- Data collection included study casts, cephalometric and panoramic radiographs and clinical photographs.
- After the orthodontic examinations and investigations, the periodontal examination and CBCT was done for each patient to evaluate the buccal bone thickness, root resorption, dehiscence, before and after surgery.
- The patients were taken up for oral prophylaxis and oral hygiene maintenance instructions were given to them

Model analysis:

- PONTS, LINDER HARTH, CHADDA'S INDEX–constricted maxillary arch
- ASHLEY HOWE'S INDEX–Borderline case
- NANCE AND CAREYS INDEX–1st premolar extraction
- ARCH PERIMETER ANALYSIS–1st premolar extraction
- BOLTONS TOOTH RATIO
- Over all maxillary tooth material is excess by 3 mm.

- Mandibular Anterior tooth ratio is excess by 1.9 mm

Diagnosis: Skeletal Class I base with prognathic maxilla and orthognathic mandible, average to vertical growth pattern. Angles class I malocclusion with proclined maxillary and mandibular incisor, class I molar relation on both right and left molar, class I canine relation on both side, potentially incompetent lip, constricted maxillary arch, non consonant smile, reduced nasolabial angle

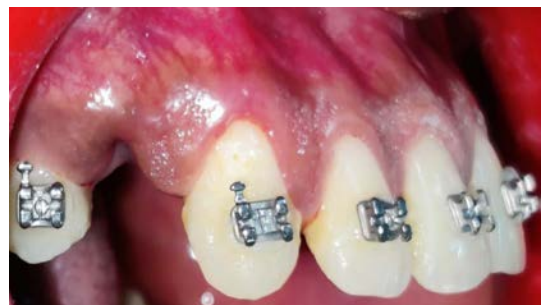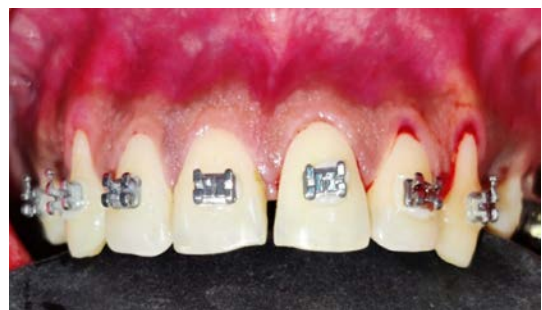Treatment objectives:

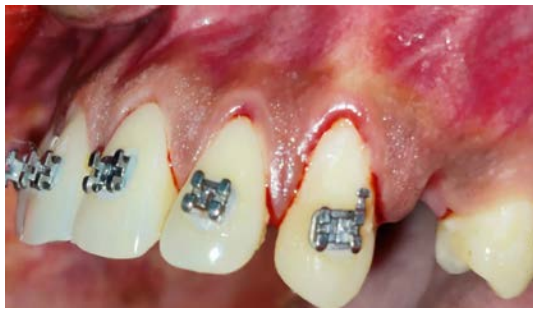Correction of:

- Proclined upper and Lower incisors,
- Potentially incompetent lip,
- Non consonant smile
- Reduced nasolabial angle
- Increased buccal corridor

Peridental surgical management: The surgical technique for PAOO consists of 5 steps:

1. Raising of flap
2. Decortication
3. Particulate grafting
4. Closure
5. Orthodontic force application





Under LA with adrenaline sulcular incision were given in maxillary anterior region from canine to canine followed by vertical incisions distal to canine.

A full thickness mucoperiosteal flap was elevated extending 3–4 mm beyond the mucogingival junction.

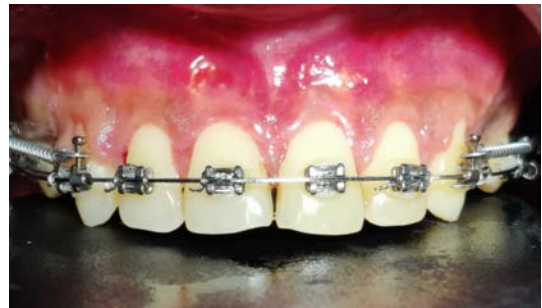With the help of a surgical carbide bur no. 2, under proper irrigation with cold saline, vertical grooves were placed in the interdicular space, midway between the root prominences in the alveolar bone on the

mesial and distal side of each tooth.

These grooves extended from a point 2–3 mm away from the crest of the bone to a point approximately 4 mm beyond the apices of the roots.

After the placement of the corticotomy cuts, Sybograft +DFDBA was placed.

The flap was adapted to normal position without tension and suturing was done.



1 MONTH POST-OPERATIVE

References:

1. Agrawal AA, Kolte AP, Kolte RA, Vaswani V, Shenoy U, Rathi P., Comparative CBCT analysis of the changes in buccal bone morphology after corticotomy and micro-osteoperforations assisted orthodontic treatment–Case series with a split mouth design. *The Saudi Dental Journal*. 2019 Jan 1;31(1):58-65.
2. Soltani L, Loomer PM, Char EE. A Novel Approach in Periodontally Accelerated Osteogenic Orthodontics (PAOO): A Case Report. *Clin Adv Periodontics*. 2019 Sep;9(3):110-114. doi: 10.1002/cap.10045. Epub 2018 Sep 28. PMID: 31490042.
3. Amit G, Jps K, Pankaj B, Suchinder S, Parul B. Periodontally accelerated osteogenic orthodontics (PAOO) - a review. *J Clin Exp Dent*. 2012 Dec 1;4(5):e292-6. doi: 10.4317/jced.50822. PMID: 24455038; PMCID: PMC3892210.
4. **THIS REFERANCE NOT VISIBL E IN PDF**



Report of an Uncommon Case: Ameloblastoma Within Dentigerous Cyst



Presented by:

Dr. Shiwani Dalal, Dept. of Oral Medicine and Radiology

Dr. Rutuja Deshmukh, Dept. of Oral and Maxillofacial surgery

Abstract: Ameloblastoma is a benign but locally aggressive odontogenic tumor, while a dentigerous cyst is a common developmental cyst associated with unerupted teeth. The coexistence of these two entities, where an ameloblastoma arises within the wall of a dentigerous cyst, represents a rare and diagnostically challenging phenomenon. This study aims to present a case report and review the clinical, radiographic, histopathological, and therapeutic aspects of this unusual condition.

Keywords: Ameloblastoma, Dentigerous Cyst, Benign tumor

Introduction: Dentigerous cyst can be defined as an odontogenic cyst that surrounds the crown of an impacted tooth; caused by fluid accumulation between the reduced enamel epithelium and the enamel surface, resulting in a cyst in which the crown is located within the lumen. This is one of the most common types of developmental odontogenic cyst, estimated to be about 20% of all jaw cysts. It is estimated that about 10% of impacted teeth have formed a dentigerous cyst. Their frequency in the general population has been estimated at 1.44 cyst for every 100 unerupted teeth. The dentigerous cyst nearly always involves or is associated with the crown of a normal permanent tooth. Seldom is a deciduous tooth involved.

Several relatively serious potential complications exist stemming from the dentigerous cyst, besides simply the possibility of recurrence following incomplete

surgical removal. Most common of them is the development of an ameloblastoma either from the lining epithelium or from rests of odontogenic epithelium in the wall of the cyst.

It is of great clinical significance as numerous cases of ameloblastoma have been reported developing in the wall of dentigerous cysts from the lining epithelium or associated epithelial rests.^[1]

Stanley and Diehl have reviewed a series of 641 cases of ameloblastoma and have found that at least 108 cases of this neoplasm, approximately 17%, were definitely associated with an impacted tooth and/or a follicular or dentigerous cyst.^[2]

The disposition for neoplastic epithelial proliferation in the form of an ameloblastoma is far more pronounced in the dentigerous cyst than in the other odontogenic cysts. The formation of such a tumor manifests itself as a nodular thickening in the cyst wall, the mural ameloblastoma, but this is seldom obvious clinically. Therefore it is not only good clinical practice, but also an absolute requisite that all tissue from dentigerous cysts be submitted to a qualified oral pathologist for thorough gross and microscopic examination.^[1]

To date, only a limited number of instances where ameloblastoma develops within the walls of a dentigerous cyst, mirroring the current case involving a 29-year-old female patient, have been documented.

Case report: A 29 year old female patient visited to the outpatient department with the



chief complaint of swelling in the lower right side of face since 1 year. Past dental history reveals history of extraction 46, 15 months back followed by fixed denture prosthesis which dislodged 5 months back. The swelling was initially of betel nut size which gradually increase to lemon size. There was no history of tooth mobility or paresthesia. No abnormalities were found during the general physical examination.

Extraoral examination revealed slight facial assymetry due to well defined swelling on lower 3rd of face on right side due to the expansile lesion intraorally with relation to 45 46 and 47.(Figure 1) A single right submandibular lymph node of size 1x1 cm which is round in shape, soft, mobile and tender on palpation.

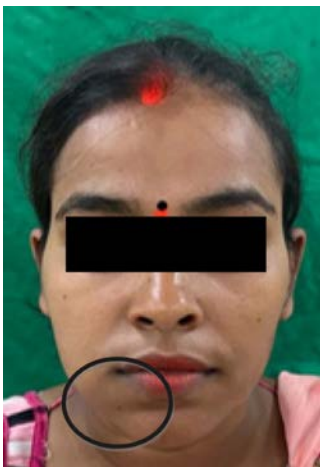

Fig 1:Extraoral facial asymmetry on right side of face

On intraoral examination, a roughly ovoid swelling with smooth surface is seen in the lower right vestibular region majorly involving right buccal vestibule with alveolar ridge of 46 of size 3x1 cm. Expansion of buccal cortical plates could also be noted. Visible pus discharge is seen from gingival sulcus distal to 43. All inspectory findings were confirmed on palpation. On palpation, the size of the swelling was 5x1 cm extending A/P from distal of 43 upto distal of 47 and S/I from alveolar ridge in the region of 46 obliterating

the lower right buccal vestibule. Expansion of buccal cortical plate and slight expansion of lingual cortical plate in the middle third of body of mandible from distal to 45 upto distal of 47 could be palpated. The swelling was non tender and bony hard on palpation. Missing teeth are present in relation to 46 and tooth preparation was seen with 45 and 47 and no tooth mobility.(Figure 2)

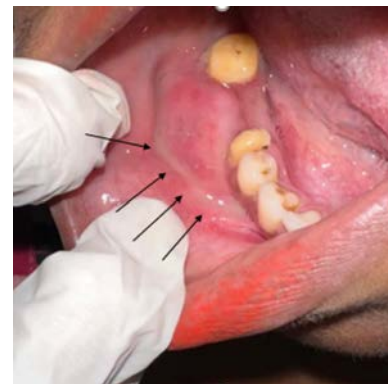

Fig 2: A) Visible pus discharge seen

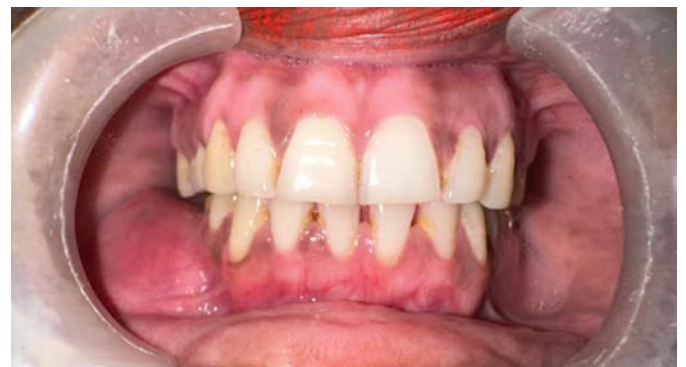

Fig 2: B) Obliteration of right buccal vestibule seen

On orthopantomogram, a well defined multilocular lesion of size approx. 7X4 cm could be seen over the right side of mandible with sclerotic borders is seen extending S/I from the alveolar crest upto right lower border of mandible and A/P from distal of 45 upto coronoid notch with impacted 48 Floating tooth appearance of 48 is noted.(Figure 3)

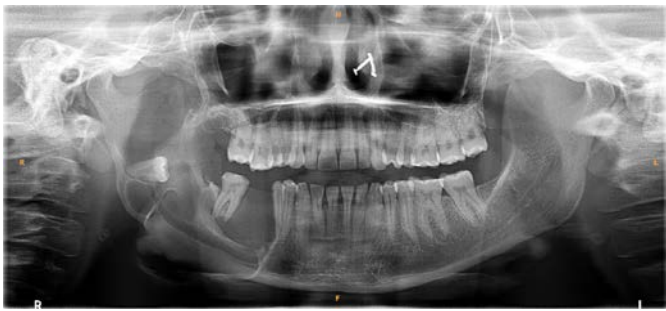

Fig 3: Orthopantomogram revealing multilocular radiolucency in the right body of mandible

Cone beam computed tomography scan revealed expansion and destruction of buccal and lingual cortical plates and root resorption with 45 and 47.(Figure 4) On the basis of clinical and radiographic findings, a provisional diagnosis of Dentigerous cyst was given.

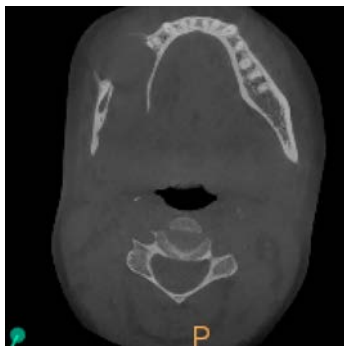

Fig 4: A) CBCT Axial section showing expansion and destruction of buccal and lingual cortical plates




Fig 4: B) CBCT Sagittal section showing impacted 48 and root resorption with 45 and 47

An incisional biopsy was performed and the specimen was sent for histopathological evaluation. The histopathological findings reveal cystic lumen lined by thin layer of epithelial cells which at places assume tall columnar shape and show stellate reticulum like cells, the epithelium at places proliferate and exhibit an extension into fibrous capsule. This capsule is fibrocellular and show areas of small odontogenic islands scattered along with bundles of collagen fibres, fibroblasts and few blood vessels. The findings were suggestive of Dentigerous cyst transforming into Ameloblastoma.(Figure 5)

Microscopic Examination: 10X magnification



Off shoots of basal cells into fibrous capsule

Fig 5: Microscopic 10X View showing off shoots of basal cells into fibrous capsule

Hemimandibulectomy was done involving the complete lesion along with normal tissue margins surrounding the lesion and free fibula graft with double barrel technique was done for rehabilitation.(Figure 6)

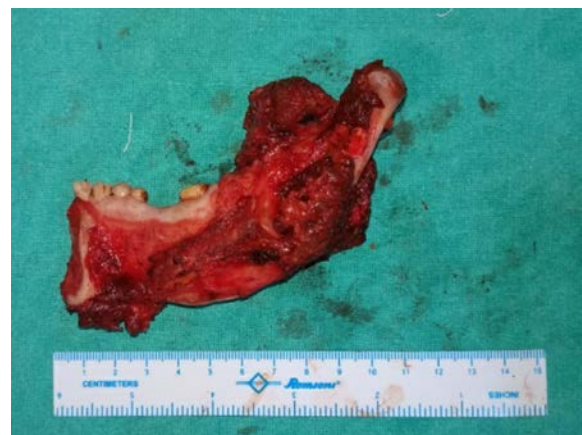

Fig 6: A) Surgically excised specimen

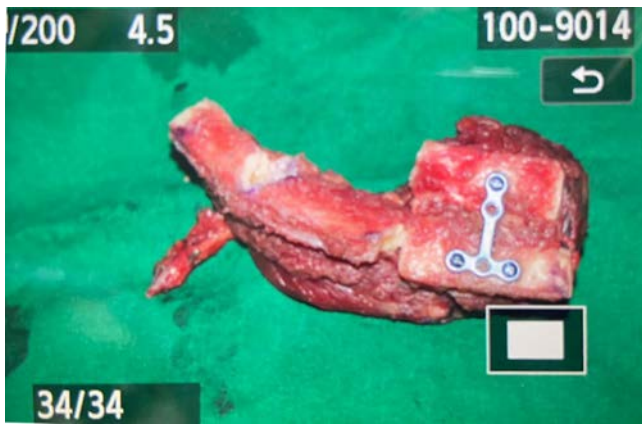


Fig 6: Free fibula graft with double barrel technique

Discussion: The presented case of a 29-year-old female patient with a history of swelling in the lower right side of her face is a notable example of the association between dentigerous cysts and ameloblastomas.

Clinical Presentation: The patient's initial presentation with facial swelling and the subsequent growth of the lesion is consistent with the clinical characteristics commonly associated with dentigerous cysts. The history of recent tooth extraction and the use of fixed denture prosthesis are noteworthy as they may contribute to the development of such cysts. Importantly, there were no reported symptoms of tooth mobility or paresthesia, which could be indicative of nerve involvement, suggesting that the lesion was relatively asymptomatic.

Radiographic and Histopathological

Diagnosis: The use of cone beam computed tomography (CBCT) played a crucial role in the diagnosis, allowing for the assessment of the lesion's extent, impact on surrounding structures and root resorption of adjacent teeth. Radiographic findings indicated expansion and destruction of buccal and lingual cortical plates, further supporting the provisional diagnosis of a dentigerous cyst.

Histopathology: Histopathological examination following incisional biopsy revealed significant insights into the lesion. The presence of a

cystic lumen lined with epithelial cells, including tall columnar cells with stellate reticulum-like features, aligns with the typical histopathological characteristics of a dentigerous cyst. Additionally, the observation of epithelial proliferation extending into the fibrous capsule is indicative of an important transformation, where the dentigerous cyst progressed into an ameloblastoma. This transformation underscores the potential complications associated with dentigerous cysts and highlights the necessity of thorough histopathological evaluation in cases of odontogenic lesions.

Treatment: The definitive treatment approach in this case involved hemimandibulectomy, which is the surgical removal of a portion of the mandible. This extensive surgical procedure was chosen due to the advanced nature of the lesion, the involvement of adjacent structures, and the transformation into ameloblastoma. Hemimandibulectomy not only ensures complete removal of the lesion but also addresses the need for clear surgical margins, minimizing the risk of recurrence.

Subsequently, reconstruction with a free fibula graft using the double-barrel technique was performed for rehabilitation. This reconstructive approach aims to restore both form and function to the mandible and allows for dental implant placement in the future.

Significance: This case underscores the potential complications associated with dentigerous cysts, especially when they transform into more aggressive entities such as ameloblastomas. As noted in the literature, ameloblastoma development in the context of a dentigerous cyst is not a common occurrence, but it does emphasize the importance of vigilant clinical assessment, timely diagnosis, and appropriate management.

The transformation of a dentigerous cyst into an ameloblastoma serves as a reminder that even seemingly benign lesions can have



significant clinical implications. Therefore, dental and oral healthcare professionals should maintain a high degree of suspicion when encountering odontogenic cysts, conduct thorough diagnostic evaluations, and collaborate with oral pathologists to ensure accurate diagnoses and appropriate treatment planning.

Conclusion: Ameloblastoma's Dentigerous

References:

1. B Sivapathasundharam. Shafer's Textbook Of Oral Pathology. 8th ed. S.L.: Elsevier India; 2020.

Cyst origin is still up for debate. The histogenesis of ameloblastomas being revealed in our current case, which is a rare instance of an ameloblastoma developing from a DC. The neoplastic potential of Dentigerous Cysts is highlighted in this case, as well as the significance of a thorough histological analysis of the entire specimen with multiple sectioning.

2. Stanley HR, Diehl RG. Ameloblastoma in the jaws of young patients. Oral Surg Oral Med Oral Pathol. 1975;40(3):340-348.



Interesting case with facial asymmetry



Presented by:
Dr. Sanika Thakur, Dept. of Orthodontics

Age: 17 YEARS Sex : FEMALE

History: Patient was apparently alright 2 years back then she experienced pain in the ear which was continuous and dull aching for which she visited private ENT practitioner where antibiotics and analgesics were given.



- Patient got relieved of the pain temporarily for 1 to 2 weeks
- She visited a private dental practitioner with the same complaint where Xrays were taken and was advised surgery for jaw correction.
- Later patient visited the department as she experienced similar episodes of pain which aggravates with cold breeze.
- The pain is same on right and left side of ear, but frequency is more on right side
- No H/O: trauma, forcep delivery



Extra oral examination:

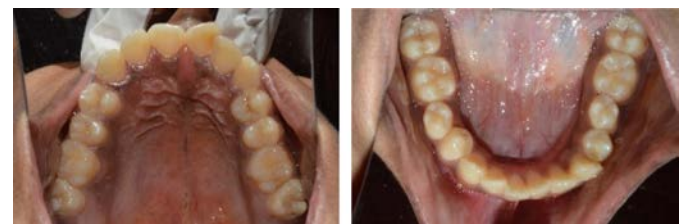- Face: Facial asymmetry seen, chin is deviated to left side
- TMJ: bilaterally palpable, slight clicking on right side, deviation towards left side



Dentition – permanent

Teeth present

17 16 15 14 13 12 11 21 22 23 24 25 26 27
 47 46 45 44 43 42 41 31 32 33 34 35 36 37



Molar relation- Class III molar relation on right and Class I on left side

Canine relation- Class III canine relation on right and end on on left side Average overjet (2mm) and average overbite (2mm)

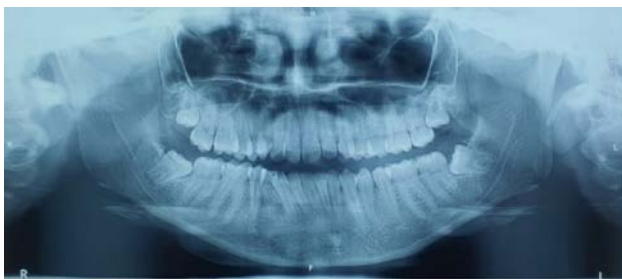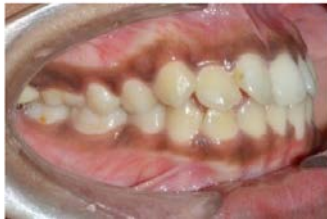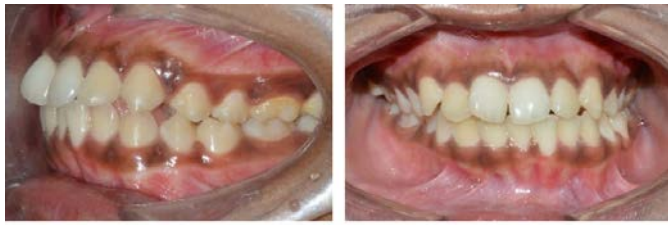Scissor bite with 17, 47

Crossbite with 25, 35

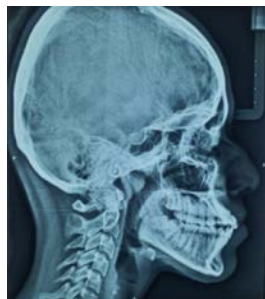Asymmetric arches (straight on right side and curved on left side of arch)



mandible present on left side, Lower midline shifted to left side by 6mm



OPG



Lateral cephalogram

MAXILLA

Measurement	Mean Value	Patient's Value	Inference
SNA	82°	82°	Orthognathic Maxilla
PN to pt. A	0+2 mm	0 mm	
NA (II to HP)	-2+3.7 mm	0 mm	
Angle of inclination	85°	84°	Average inclination of Maxillary Hash Anteriorly

Inference : Orthognathic Maxilla

MAXILLA

Measurement	Mean Value	Patient's Value	Inference
Effective Maxillary Length	87.0 + 4.3 mm	73 mm	Maxillary Length is reduced
N ANS	50.2 + 3.4 mm	46 mm	Middle third face is reduced
N PNS	50.6 + 1.2 mm	46 mm	Posterior Maxillary Height is reduced

MANDIBLE

Measurement	Mean Value	Patient's Value	Inference
SNB	80°	82°	Prognathic Mandible
SND	76°	80°	Prognathic Chin
N-B (II to HP)	6.9+4.3 mm	-1 mm	Prognathic Mandible
N-Pog (II to HP)	6.5+5.1 mm	1 mm	Prognathic Chin
Facial angle/ Depth	87.8°	92°	Prognathic Chin

MANDIBLE

Measurement	Mean Value	Patient's Value	Inference
Effective mandibular length	120+2.3 mm	103 mm	Reduced mandibular length
Ar Go	46.8+ 4.5 mm	37 mm	Reduced Ramal Height
Ar-Pun	32.1+1.9 mm	31 mm	Average position of mandible WRT to post surface of maxilla

MAXILLO-MANDIBULAR SKELETAL RELATION

Measurement	Mean Value	Patient's Value	Inference
ANU	2°	0°	Class III skeletal relation
angle of convexity	0° (-8.5 to -10°)	-3	Straight profile
Wits appraisal	-4.5 to 1.5 mm	-4 mm	Class III skeletal relation
Angle of inclination	27° - 33°	40°	Class III skeletal relation

Inference : Class III skeletal relation



GROWTH PATTERN

Measurement	Mean Value	Patient's Value	Inference
Go Gn to SN	32°	32°	Average growth pattern
Mandibular plane angle	21.9°	29°	Vertical growth pattern
FMPA	25°	29°	Vertical growth pattern
Y-Axis	59.9°	60°	Average growth pattern
Jarabak Ratio	62-65%	63%	Average growth pattern
Basaal plane angle	25°	25°	Average overbite

POSITION OF UPPER INCISORS

Measurement	Mean Value	Patient's Value	Inference
1 to NA	22°	39°	proclined upper incisors
1 to NA (mm)	4 mm	20 mm	
1 to A-Pog (mm)	4-6 mm	9 mm	
1 to SN plane	102°	120°	
1 to NF	27.5+1.7	24 mm	Reduced upper dental height

Inference Proclined upper incisors

POSITION OF LOWER INCISORS

Measurement	Mean Value	Patient's Value	Inference
1 to NB	25°	32°	Proclined lower incisors
1 to NB (mm)	4 mm	7 mm	
1 to A-Pog	1-3 mm	7 mm	
IMPA	90°	95°	
1 to MP (mm)	40.8+1.8 mm	33 mm	Reduced lower anterior dental height

Inference : Proclined lower incisors

SOFT TISSUE ANALYSIS

Measurement	Mean Value	Patient's Value	Inference
Facial angle	90 ± 3°	91°	Average facial angle
Nasolabial angle	102 ± 4°	91°	Reduced nasolabial angle
Convexity at point A	2 ± 2 mm	0 mm	Straight profile
H-line angle	7-15	13°	Average upper lip position
Upper lip curvature	2-5 mm	3 mm	Average
Upper sculus depth	5 mm	4 mm	Average

SOFT TISSUE ANALYSIS

Measurement	Mean Value	Patient's Value	Inference
Upper lip thickness	15 mm	14 mm	Average thickness
Upper lip strain	2 mm	6 mm	Strain present
Lower lip H line	0 mm	3 mm	Protruded lower lip
Lower sulcus depth	5 mm	2 mm	Reduced sulcus depth
Soft tissue chin thickness	10-12 mm	8 mm	Reduced soft tissue chin thickness

RAKOSI ANALYSIS

ANGLE	AVERAGE	PATIENT VALUE	INFERENCE
Saddle angle	123 ± 5°	121°	Average position of Condyle W.R.T. cranial base
Articular angle	143 ± 6°	146°	Average position of mandible
Gonial angle	128 ± 7°	127°	Average growth pattern
Upper gonial angle	55-55°	52°	
Lower gonial angle	72 - 75°	75°	
Sum	396 ± 6°	394°	Average rotation of mandible



SCHWARTZ ANALYSIS

RATIO	Mean Value	Patient's Value	Inference
N-Sc Max base	10/7-1.4	1.30	Reduced; as maxillary base length is excess by 4 mm
N-Sc Mand base	20/21-0.95	0.82	Mandibular base is excess by 10 mm
Max base: Mand base	2/3-0.66	0.63	Increased as maxillary base length is less by 2 mm
Ramus length: Mand base	5/7-0.71	0.65	ramus less by 3 mm

GRUMMON'S ANALYSIS

Parameter	Right	Left	Difference
CO-AG	60 mm	55 mm	5 mm
AG-ME	47 mm	37 mm	10 mm
CO-ME	97 mm	85 mm	12 mm
CO-AG-ME	132°	134°	2°
CO-MSR	47 mm	40 mm	7 mm
C-MSR	13 mm	13 mm	0 mm
J-MSR	27 mm	30 mm	3 mm
AG-MSR	30 mm	40 mm	10 mm

Inference: Length of ramus and body of mandible is more on right side

Transverse Relation: Constricted maxillary and mandibular arch.

Sagittal Relation: Class III molar relation on right and Class I left side, Class III canine relation on right and End on on left side average overjet

- Vertical Relation: Average overbite
 - Model analysis
 - Ponts, Linder Harth, Chadda's Index - Constricted maxillary arch.
 - Ashley Howe's Index - Borderline case
 - Arch Perimeter Analysis - 1st premolar extraction in upper arch
 - Nanace and Creys Index - 1ST premolar extraction in lower arch.
 - Boltons Tooth Ratio
- Overall ratio - Mandibular tooth material

is excess by 1.5 mm

Anterior ratio - Mandibular tooth material is excess by 0.4 mm

SPACE ANALYSIS

Space Required	Maxillary Arch	MANDIBULAR ARCH
Proclination	14 mm	10 mm
Derotation	-	-
Labio/Lingo Version	-	-
Crowding	2 mm	2 mm
Curve of spee	-	-
Net	16 mm	12 mm

SPACE ANALYSIS

Space Available	Maxillary Arch	MANDIBULAR ARCH
Interdental Spacing	1 mm	-
Retroclination of incisors	-	-
Derotation of Premolars	-	-
Interproximal Stripping	-	-
Expansion of Arch	1 mm	-
Extraction of Teeth	14 mm	14 mm
Distalization of Molars	-	-
Net	16 mm	14 mm

TREATMENT PLANNING:

Department of Oral medicine and Radiology: Radiographs such as TMJ sections are advised

Advanced radiographic techniques such as CBCT, MRI and Scintigraphy to rule out the cause of asymmetry.

Department of Prosthodontics:

- TMJ disorders (TMD) refers to a group of disorders with symptoms that include pain, clicking, noise, grating in the jaw joint or problems chewing or opening the jaw.



- The signs and symptoms of TMD commonly include pain, joint sounds (clicking, grating), and limited or asymmetrical jaw movement that may have an effect on the quality of life.
- Treatment options for TMD include reassurance (patient education, self-care and behaviour therapy), physiotherapy (such as ultrasound, acupuncture, short wave diathermy, laser, heat exercises, and biofeedback), occlusal splint therapy, drug therapy, occlusal adjustment, surgical intervention and combined treatment.

Occlusal Appliances (splints) Materials:



- 1 Commonly there are two different materials, based upon consistency, which are used in the fabrication of occlusal appliances.
- 2 There are hard acrylic resin Occlusal appliances that are either selfcured (by chemical reaction) or heat cured, resulting in hard and rigid tooth-borne and occlusal surface.
- 3 In other hand, there are soft or resilient occlusal appliances, the soft appliance are somewhat flexible and pliable tooth-borne and occlusal surface.

Types of Oral appliance for Treatment of TMD: Classification of occlusal appliances according to Okeson include

- 1) Muscle relaxation appliance/ stabilization appliance used to reduce muscle activity
- 2) Anterior repositioning appliances
- 3) Orthopedic repositioning appliance
- 4) Anterior bite plane
- 5) Pivoting appliance
- 6) Soft/ resilient appliance

Classification of occlusal appliances according to Dawson include:

- 1) Permissive splints/muscle deprogrammer
- 2) Directive splints/ non-permissive splints
- 3) Pseudo permissive splints (e.g. Softsplints, Hydrostatic splint)

DC/TMD Format for the Assessment of type of Temporomandibular disorder:

DC/TMD Examination Form

Patient _____ Examiner _____ Date filled out (mm-dd-yyyy) _____

1a. Location of Pain: Last 30 days (Select all that apply)

RIGHT PAIN None Temporalis Other m muscles Non-mast structures Masseter TMJ

LEFT PAIN None Temporalis Other m muscles Non-mast structures Masseter TMJ

1b. Location of Headache: Last 30 days (Select all that apply)

None Temporal Other

2. Incisal Relationships Reference tooth #8 #9 #10 Other

Horizontal Incisal Overjet if negative [] mm Vertical Incisal Overlap if negative [] mm Midline Deviation Right Left N/A [] [] [] mm

3. Opening Pattern (Supplemental): Select all that apply

Straight Corrected deviation Uncorrected Deviation Right Left

4. Opening Movements

A. Pain Free Opening [] mm

	RIGHT SIDE			LEFT SIDE		
	Pain	Familiar Pain	Familiar Headache	Pain	Familiar Pain	Familiar Headache
B. Maximum Unassisted Opening [] mm	Temporalis	Temporalis	Temporalis	Temporalis	Temporalis	Temporalis
	Masseter	Masseter	Masseter	Masseter	Masseter	Masseter
	TMJ	TMJ	TMJ	TMJ	TMJ	TMJ
	Other M Musc	Other M Musc	Other M Musc	Other M Musc	Other M Musc	Other M Musc
	Non-mast	Non-mast	Non-mast	Non-mast	Non-mast	Non-mast
C. Maximum Assisted Opening [] mm	Temporalis	Temporalis	Temporalis	Temporalis	Temporalis	Temporalis
	Masseter	Masseter	Masseter	Masseter	Masseter	Masseter
	TMJ	TMJ	TMJ	TMJ	TMJ	TMJ
	Other M Musc	Other M Musc	Other M Musc	Other M Musc	Other M Musc	Other M Musc
	Non-mast	Non-mast	Non-mast	Non-mast	Non-mast	Non-mast
D. Terminated? <input type="radio"/> <input type="radio"/>	Temporalis	Temporalis	Temporalis	Temporalis	Temporalis	Temporalis
	Masseter	Masseter	Masseter	Masseter	Masseter	Masseter
	TMJ	TMJ	TMJ	TMJ	TMJ	TMJ
	Other M Musc	Other M Musc	Other M Musc	Other M Musc	Other M Musc	Other M Musc
	Non-mast	Non-mast	Non-mast	Non-mast	Non-mast	Non-mast

5. Lateral and Protrusive Movements

	RIGHT SIDE			LEFT SIDE		
	Pain	Familiar Pain	Familiar Headache	Pain	Familiar Pain	Familiar Headache
A. Right Lateral [] mm	Temporalis	Temporalis	Temporalis	Temporalis	Temporalis	Temporalis
	Masseter	Masseter	Masseter	Masseter	Masseter	Masseter
	TMJ	TMJ	TMJ	TMJ	TMJ	TMJ
	Other M Musc	Other M Musc	Other M Musc	Other M Musc	Other M Musc	Other M Musc
	Non-mast	Non-mast	Non-mast	Non-mast	Non-mast	Non-mast
B. Left Lateral [] mm	Temporalis	Temporalis	Temporalis	Temporalis	Temporalis	Temporalis
	Masseter	Masseter	Masseter	Masseter	Masseter	Masseter
	TMJ	TMJ	TMJ	TMJ	TMJ	TMJ
	Other M Musc	Other M Musc	Other M Musc	Other M Musc	Other M Musc	Other M Musc
	Non-mast	Non-mast	Non-mast	Non-mast	Non-mast	Non-mast
C. Protrusion [] mm	Temporalis	Temporalis	Temporalis	Temporalis	Temporalis	Temporalis
	Masseter	Masseter	Masseter	Masseter	Masseter	Masseter
	TMJ	TMJ	TMJ	TMJ	TMJ	TMJ
	Other M Musc	Other M Musc	Other M Musc	Other M Musc	Other M Musc	Other M Musc
	Non-mast	Non-mast	Non-mast	Non-mast	Non-mast	Non-mast

if negative

Provisional Diagnosis: Myofacial Pain Dysfunction Syndrome secondary to occlusal derangement, along with overload of lateral and medial pterygoid muscles.

Treatment plan:

- Initially a soft splint appliance was given to the patient for 15 days as a means of symptomatic relief, until a definitive splint is fabricated.
- As the contralateral condyle can translate normally, stabilization splint of 2 mm thickness will be made for the upper arch,



in canine guided occlusion after written informed consent.

Department of Orthodontics:

Pre-surgical orthodontic phase

- Leveling alignment.
- Lower 1st premolar extraction space closure keeping moderate anchorage.

Post-surgical orthodontic phase:

- Settling the occlusion.

Retention phase:

- Activator for 1 year.

Department of Oral and Maxillofacial Surgery:

Surgical phase:

- Bilateral sagittal split ramus osteotomy with more setback on right side.

Conclusion: For the treatment of this asymmetry a multidisciplinary approach is required. Thus can be a learning opportunity for various departments to blend and work together.



Case report on central giant cell granuloma

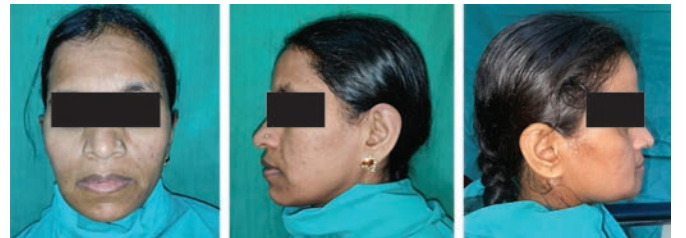

Presented by:

Dr. Adit Hawelkar, Dept. of Oral and Maxillofacial surgery

Introduction: The central giant cell granuloma (CGCG) of the jaws is usually a nonneoplastic bone lesion accounting for fewer than 7% of all benign tumors of the jaws. The histologic features of CGCG have been discussed extensively. They are defined by the World Health Organization as an intraosseous lesion consisting of cellular fibrous tissue containing multiple foci of hemorrhage, aggregations of multinucleated giant cells, and occasionally, trabeculae of woven bone. CGCG of the jaws mainly occurs in children or in young adults, with a predilection for females. It is more common in the mandible than in the maxilla and can be confined to the tooth-bearing areas of the jaws. CGCGs can also affect extragnathic bones, mainly in the craniofacial region, and small long bones such as those of the hands and feet. The radiologic features of the CGCG comprise a unilocular or a multilocular radiolucency and varying degrees of expansion of the cortical plates. The biologic behavior of CGCGs ranges from a slowly growing asymptomatic swelling to an aggressive process associated with pain, cortical bone destruction, root resorption, displacement of teeth, and a recurrence rate between 13% and 49%. The definitive treatment approach in this case involved segmental resection, which is the surgical removal of a portion of the mandible. This extensive surgical procedure was chosen due to the advanced nature of the lesion and its unresponsive nature to steroid therapy.

Case Report: 37 year old female patient visited to the outpatient department with the chief complaint of swelling in the lower right side of face since 6 months. The swelling was initially of pea size which gradually increase to thrice the original size. There was no history of tooth mobility or paraesthesia. There was no history of any fever or discharge. There was no similar history of swelling in the past or similar swellings elsewhere in the body. Patient gives history of hypothyroidism but was not under the medications for the same.

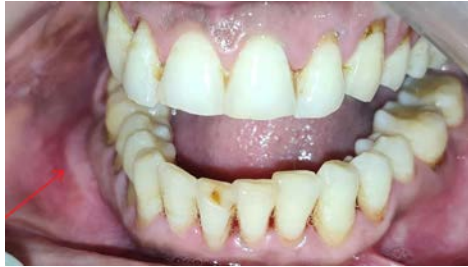

Extraoral facial asymmetry on the right side of the face.

Extraoral examination revealed slight facial asymmetry due to swelling on lower 3rd of face on right side which extended supero-inferiorly 1 cm below right corner of the mouth upto the inferior border of mandible and anteroposteriorly from right corner of mouth upto 3cm anterior to angle of mandible. Skin over the swelling appeared normal and there was no discharge present. On palpation, consistency of swelling was bony hard, it was fixed, non-fluctuant and there was no tenderness or discharge on provocation present. No egg shell crackling was noted.

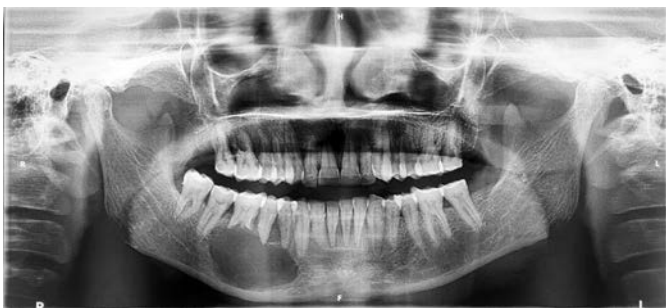

Intraoral examination revealed obliteration in right lower vestibule opposite to 44,45,46. Grade II mobility was noted with respect to 43 and 46 and Grade I mobility was noted with 44. On palpation, elevation was noted in the lower right vestibule opposite to 45,46 which hard in consistency, non-tender and no discharge on provocation.



Intraoral swelling shown obliterating lower buccal vestibule

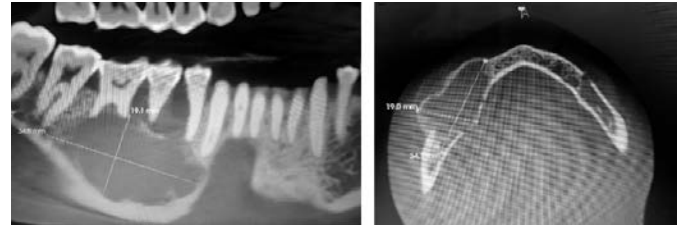
On orthopantomogram, a well defined unicystic lesion of size approx. 4X3cm could be seen over the right side of mandible is seen extending S/I from the alveolar crest upto right lower border of mandible and A/P from distal of 43 upto mesial portion of 47.



Orthopantomogram shows a well defined, roughly oval, unilocular radiolucency with no corticated borders extending anteroposteriorly from distal aspect of 43 upto mesial aspect of 47 and superoinferiorly from 3mm inferior to alveolar crest of 46 upto 2mm above inferior border of mandible.

Cone beam computed tomography scan revealed expansion of buccal and lingual cortical plates. Root resorption was noted

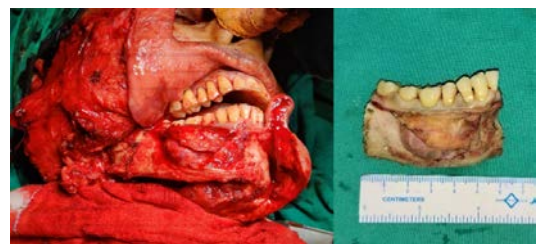with 44,45,46. On the basis of clinical and radiographic findings, a provisional diagnosis was

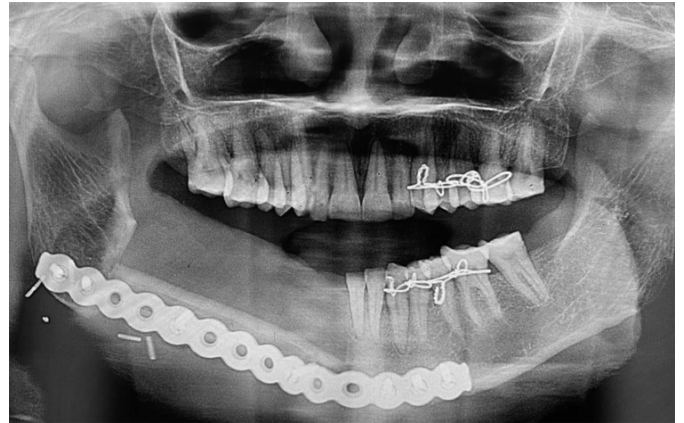
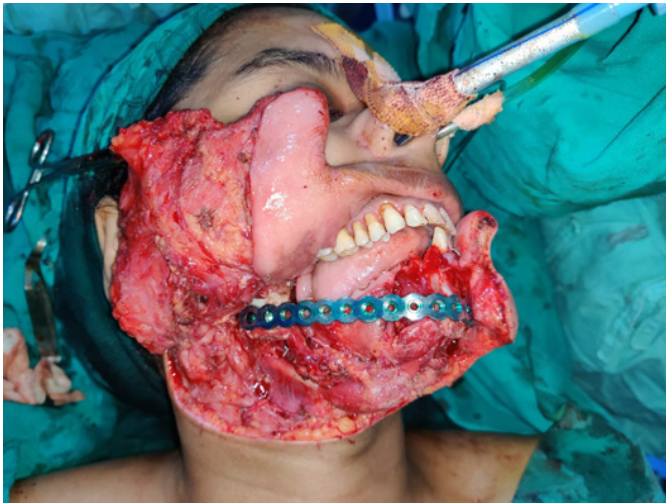

Axial and Sagittal section showing expansion of buccal and lingual cortical plates.

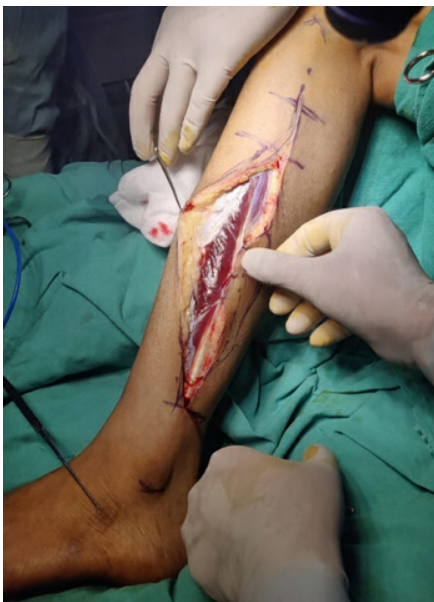An incisional biopsy was performed and the specimen was sent for histopathological evaluation. The histopathological findings multinucleated giant cells, in a cellular vascular stroma, and often-new bone formation were demonstrated. The osteoclast-like giant cells with patchy distribution were seen. Also, the proliferating cells include spindle-shaped fibroblasts, myofibroblasts, and inflammatory mononuclear cells were seen. The findings were suggestive of central giant cell granuloma.

Treatment: Initially, patient was put on intralesional corticosteroid therapy as it is reported to decrease the inflammatory response within the lesion. Patient was put on corticosteroid therapy for 6 weeks wherein every week one dose of intra lesional injection was given to the patient. On completion of therapy, it was observed that there was no regression in the size of the lesion and hence surgical treatment was planned next. Segmental resection was done from 42 to 47 and reconstruction was done using free fibula graft.





Segmental resection of right side of mandible with reconstruction using free fibula graft and fixation using 2.5mm reconstruction plate



Conclusion: definitive approach to the pathology remained surgical treatment as corticosteroid therapy failed to show the regression of the result. But, there are studies that shows that corticosteroid therapy worked successfully in CGCG lesion as it considered reparative lesion. There are other studies where calcitonin therapy and interferon alpha therapy have shown to terminate the rapid growth of the lesion.

Surgical approach still remains the main stay treatment. Segmental resection not only ensures complete removal of the lesion but also addresses the need for clear surgical margins, minimizing the risk of recurrence.

Referances:

1. 1. de Lange J, van den Akker HP, van den Berg H. Central giant cell granuloma of the jaw: a review of the literature with emphasis on therapy options. Oral Surgery, Oral Medicine, Oral Pathology, Oral Radiology, and Endodontology. 2007 Nov 1;104(5):603-15.
2. De Lange J, Van den Akker HP, Van Zanten GV, Engelshove HA, Van den Berg H, Klip H. Calcitonin therapy in central giant cell granuloma of the jaw: a randomized double-blind placebo-controlled study. International journal of oral and maxillofacial surgery. 2006 Sep. 1;35(9):791-5.



Conservative Surgical Management of An Odontoma in 11 Year Old Child.



Presented by:

Dr. Samiksha Dharampuria, Dept. of Pediatric and preventive dentistry

Dr. Rakshata Sortey, Dept. of Oral Pathology

The most prevalent type of odontogenic tumors are odontomas, which are caused by the formation of fully differentiated mesenchymal and epithelial cells. Dentin and enamel are what make them up, although they may also contain varying quantities of cementum and pulp tissue. Etiology being local trauma, inflammatory processes, and chronic infections during odontogenesis, genetic background, such as odontoblastic hyperactivity, or hereditary syndromes like Gardner's syndrome and Hermann's syndrome. Odontomas can be tooth like structures [compound] or undifferentiated [complex].

Chief Description: An 11 year old male patient reported to the department of Pediatric and Preventive Dentistry with the chief complaint of decayed tooth in lower left back region of jaw since 1 month.

Patient was apparently alright 1 month ago, then mother noticed decayed milk tooth in lower left back region of jaw. Parent also complained of non-exfoliation of the same tooth. No history of pain, swelling or fever was present. History of restoration with the same tooth. Medical history was non-contributory. Dental history – history of restoration 75 and pulpectomy with 84 85, 3 years back.

Extraoral Examination revealed Symmetrical face with convex profile, Competent lips and TMJ with No tenderness, clicking, crepitus, mobility Intraoral examination showed

- Mixed dentition with U-shaped maxillary and mandibular arches, Palatal pit caries

with 16,26, Root piece with 54 and Rotation with 14,15, Missing blocked out 13, ectopic eruption of 23.

- Anterior crowding in lower anterior [mild] and Over retained deciduous teeth with 75, Pit and fissure caries with 46,36

Hence a Provisional Clinical Diagnosis was made indicating Over retained deciduous teeth with 75., Angles class III molar relationship on right side and class II on left side and Impacted canine with 13

Radiographic examination: Radiographs showed Radiolucency surrounding the restoration seen with crown of 75. There were 2 small radio-opaque tooth like structures in inter radicular area of 75.

Large ovoid structure = 3.6 x 3.3 mm

Small round structure = 2.6 x 2.3 mm

They were surrounded by a thin radiolucent zone and impacted 35 with slight open apex. Further detailed Investigations were conducted including OPG, CBCT, Hemogram Histopathologic examination for coming to a final diagnosis.

Hence a Provisional Diagnosis was given as Compound odontoma with 75.

Differential Diagnosis:

- Ameloblastic odontoma
- Ameloblastic fibro odontoma

Treatment plan included:

- Preparatory and preventive phase
Complete oral prophylaxis, Preventive Resin Restoration with 46, 36, 16 and 26



- Surgical phase

Extraction with 75, Conservative surgical enucleation of odontoma with 75.

Under local anesthesia (2% lignocaine with 1 : 100,000 epinephrine) the extraction of over retained deciduous tooth was carried out. To access the odontoma, an opening was created in the floor of the distal surface of furcal bone. The adjacent floor of distal root socket was removed using surgical round bur under continuous drip irrigation.

The calcified teeth like structures along with the fibrous capsule were removed without disturbing the unerupted premolar with right apexo surgical elevator.

Hemostasis was achieved, post-extraction instructions was given and calcified teeth like structures were sent for histologic assessment.

Follow up of 1 week to check healing, 2-3 month follow up for any spontaneous eruption along with lingual arch for space management.

Histopathologic assessment revealed tooth like structures.

Final Diagnosis: Compound odontoma with 75

Discussion: The WHO divides odontomas into complicated (CxOD) and compound (CpOD)

References:

1. Shafer WG, Hine MK, Levy BM. Cysts and tumours of the jaws. In: A Textbook of Oral Pathology. 4th ed. Philadelphia: WB Saunders Company; 1997. p. 308-311.
2. Hidalgo-Sánchez O, Leco-Berrocal MI, Martínez-González JM. Meta analysis of the epidemiology and clinical manifestations of odontomas. *Med Oral Patol Oral Cir Bucal* 2008;13:E730-4.
3. Waldron AC. Odontogenic cysts and tumours. In: Neville BW, editor. *Oral and Maxillofacial Pathology*. 2nd ed. Philadelphia: WB Saunders Company; 2002. p. 631-2.
4. De Oliveira BH, Campos V, Marçal S. Compound odontoma-Diagnosis and treatment: Three case reports. *Pediatr Dent* 2001;23:151-7.
5. Dagıstan S, Goregen M, Miloglu Ö. Compound odontoma associated with maxillary impacted permanent central incisor tooth: A case report. *Internet J Dental Sci* 2007;5:
6. White SC, Pharoah MJ. Benign tumours of the jaws. In: *Oral Radiology: Principles and Interpretation*. 5th ed. Missouri:

odontomas.

based on the organisation and differentiation of the odontogenic cells. A complicated odontoma is an amorphous mass that results from the connective tissue separating calcified dental tissue that is less differentiated than normal dental tissue from the surrounding bone.

Based on the radiographic findings, the patient presented in this report was first identified as a complex odontoma.

Manjakandy S. et.al and Rana V. et.al reported surgical excision method for removal of odontoma. The removal of odontoma by surgical removal method causes damage to nerve, injury to nearby teeth, infection and postoperative paresthesia.

In present case, conservative technique was used for removal of odontoma. This technique was implemented for the 1st time (extraction through floor of alveolar socket).

Conclusion: The introduction of a new surgical approach for odontoma removal holds significant clinical importance in pediatric dentistry. This innovative technique offers improved outcomes by minimizing complications, facilitating faster healing, and enhancing the preservation of impacted teeth.



- Mosby; 2004. p. 424-8.
7. Cawson RA, Odell EW. Odontogenic tumours and tumour like lesions of the jaws. In: Essentials of Oral Pathology and Oral Medicine. 6th ed. Edinburgh: Churchill Livingstone; 1998. p. 117-31.
 8. Troeltsch M, Liedtke J, Troeltsch V, Frankenberger R, Steiner T, Troeltsch M. Odontoma associated tooth impaction: accurate diagnosis with simple methods? Case report and literature review. J Oral Maxillofac Surg. 2012;70(10):e516-20.
 9. Tomislav Ćabov Odontomas: pediatric case report and review of the literature, acta clin Croat 2021.
 10. Satish V, Prabhadevi MC, Sharma R. Odontome: a brief overview. Int J Clin Pediatr Dent. 2011;4(3):177-85.
 11. Rana V, Srivastava N, et al. Compound Odontome: A Case Report. Int J Clin Pediatr Dent, 2019;12(1):64-67.
 12. Smitha Manjakandy, Paul ST, Bagga V. Surgical Management of Compound Odontome Associated with Impacted Canine: A Case Report. J South Asian Assoc Pediatr Dent, 2019;2(2):64-68.



Published by:
Ranjeet Deshmukh Dental College and Research Center
Hingna, Nagpur

